



doi • 10.5578/tt.20219912
Tuberk Toraks 2021;69(1):98-101
Geliş Tarihi/Received: 30.12.2020 • Kabul Ediliş Tarihi/Accepted: 19.01.2021

OLGU SUNUMU
CASE REPORT

Thyroid gland metastasis mimicking thyroid carcinoma in a lung cancer patient and dramatic response to crizotinib: A case report

Enes ERUL¹(ID)
Deniz Can GÜVEN²(ID)
Taha Koray ŞAHİN¹(ID)
İbrahim GÜLLÜ²(ID)

¹ Department of Internal Medicine, Hacettepe University Faculty of Medicine, Ankara, Turkey

¹ Hacettepe Üniversitesi Tıp Fakültesi, İç Hastalıkları Anabilim Dalı, Ankara, Türkiye

² Department of Oncology, Hacettepe University Faculty of Medicine, Ankara, Turkey

² Hacettepe Üniversitesi Tıp Fakültesi, Onkoloji Anabilim Dalı, Ankara, Türkiye

ABSTRACT

Thyroid gland metastasis mimicking thyroid carcinoma in a lung cancer patient and dramatic response to crizotinib: A case report

Metastasis of lung adenocarcinoma to the thyroid is extremely rare. Since treatment for primary thyroid cancer and non thyroid malignancy is totally different, precise diagnosis is clinically important.

Key words: Thyroid metastasis; non-small cell lung cancer; adenocarcinoma; crizotinib

ÖZ

Primer tiroid kanseriyle karışan akciğer adenokanserinin tiroid bezine metastazı ve crizotinib ile dramatik yanıt: Olgu sunumu

Akciğer adenokarsinomunun tiroide metastazı oldukça nadirdir. Primer tiroid kanseri ve tiroid dışı malignite tedavisi tamamen farklı olduğundan, kesin tanı klinik olarak önemlidir.

Anahtar kelimeler: Tiroid metastazi; khdak; adenokarsinom; crizotinib

INTRODUCTION

Metastasis of lung adenocarcinoma to the thyroid gland is extremely rare, although it should be kept in mind especially in patients with unusual features like the presence of metastases in the initial presentation. Accurate diagnosis is of paramount importance, since treatment for primary thyroid cancer and extra-thyroidal malignancy is completely different. However, it is

Cite this article as: Erul E, Güven DC, Şahin TK, Güllü İ. Thyroid gland metastasis mimicking thyroid carcinoma in a lung cancer patient and dramatic response to crizotinib: a case report. Tuberk Toraks 2021;69(1):98-101.

Yazışma Adresi (Address for Correspondence)

Dr. Enes ERUL
Hacettepe Üniversitesi Tıp Fakültesi,
İç Hastalıkları Anabilim Dalı,
ANKARA - TÜRKİYE
e-mail: eneserul@hotmail.com

©Copyright 2021 by Tuberculosis and Thorax.
Available on-line at www.tuberktoraks.org.com

difficult to distinguish the two different conditions by histopathological features only due to frequent TTF-1 expression in both conditions (1). Molecular analyses can aid to differential diagnosis and also aid to treatment decisions by identifying targetable mutations in these difficult cases, although the experience is limited. Herein, we report a case of ROS1 mutant lung adenocarcinoma mimicking thyroid carcinoma with its' treatment.

Case Presentation

A 67-year-old Caucasian woman applied to a local hospital in January 2019 because of a painless lump in her neck. The patient was euthyroid and didn't have history of dyspnea, dysphagia, or dysphonia. Ultrasound examination was remarkable for a diffusely enlarged thyroid gland and multiple cervical lymphadenopathies. A fine needle aspiration cytology for cervical lymph nodes revealed findings suggestive of a thyroid malignancy with the positive TTF-1 expression, although typical nuclei findings of papillary thyroid carcinoma were absent. The patient underwent a total thyroidectomy and bilateral neck lymph node dissection with the preliminary diagnosis of a poorly differentiated thyroid gland malignancy. After the surgery the patient applied to our clinic for a second opinion. The re-evaluation of thyroidectomy material in our hospital interpreted as the lung adenocarcinoma. A subsequent PET scan revealed intense uptake in a lung nodule of 1 cm diameter, lymph nodes on the cervical, right hilar, mediastinal, thyroid and bones (Figure 1A). Molecular analyses for epidermal growth factor receptors, anaplastic lymphoma kinase and ROS was ordered and showed positivity for the ROS fluorescence in situ hybridization (FISH). The patient started treatment with crizotinib and a complete metabolic response was seen in all lesions after the 3 months of treatment (Figure 1B). The patient is still alive and well with a continuing complete response in the 15th month of crizotinib treatment.

DISCUSSION

The metastases to the thyroid gland are uncommon and constitute 1-3% of all the thyroid neoplasms (2-4). Despite its rich vascularity, the thyroid relatively protected from metastasis for these stated reasons: First, most of the malignant tumor cells enter the venous circulation. Second, those cells which succeed in reaching the thyroid bed are always washed

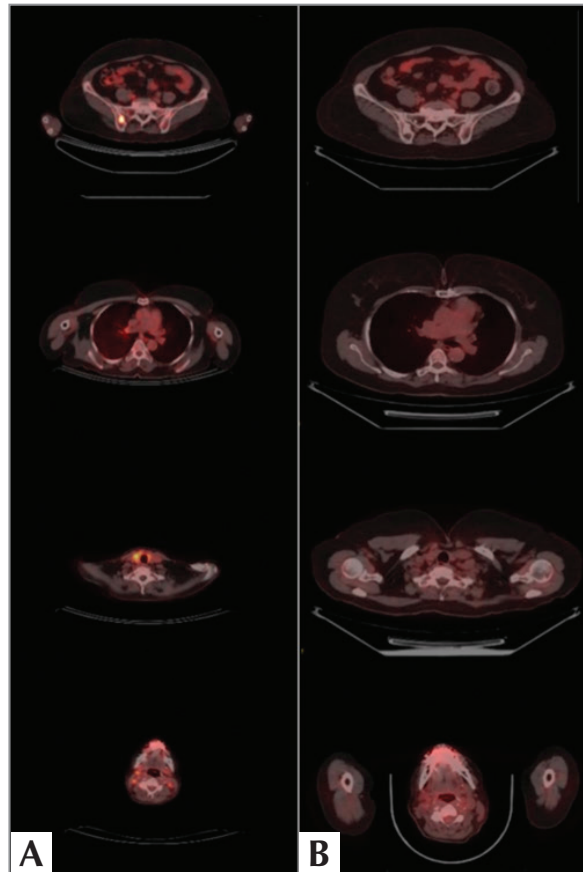


Figure 1. A. PET scan revealing intense uptake in a lung nodule of 1 cm diameter, lymph nodes on the cervical, right hilar, mediastinal, thyroid and bones **B.** A complete metabolic response in all lesions after the 3 months of crizotinib treatment.

away due to the effects of high intraglandular blood flow and the tumoricidal effect of high intraglandular oxygen and iodine content (5,6). Statistically, kidney is the most common primary cancer responsible for metastases to thyroid gland, followed by the lung and breast cancers in the majority of the Western series (7,8), whereas lung, breast, and stomach are the most common primary cancer sites (in decreasing order) reported in the data from Far East (9,10). Adenocarcinoma is the most common histology in patients with lung cancers metastasizing to the thyroid, in order of squamous cell, small cell, and large cell similar to frequencies in the general population (1,11). Direct spread, hematogenous metastases, and lymphatic metastases are the three main ways with the hematogenous spread being the most common route for thyroid metastases. For lung cancer, a direct invasion of the malignant tumor from the adjacent organs such as the larynx, trachea, or esophagus is

the most frequent route of metastasis to thyroid gland (11).

Clinically, thyroid metastases have some distinctive clinical manifestations including a hard, fixed, rapidly growing mass, a peripheral infiltration, and a cervical lymph node metastasis. Compressive symptoms such as dyspnea, dysphagia, or dysphonia might be seen in some cases. Unfortunately, these symptoms aren't specific and may be misdiagnosed as primary thyroid cancer or as a benign tumor (1,11).

Fine needle aspiration (FNA) through ultrasound guidance can help diagnose nonthyroid metastasis because of its quick, minimally invasive, and cheaper approach features. Nonetheless, FNA may not be sufficient for the exact origin of primary tumor (12). Although core-biopsy and surgical biopsies can be more precise, the diagnosis can still be challenging. It might be much more misleading when the thyroid metastasis presents in the absence of an antecedent history of another primary cancer or present synchronously as it was in our case (13).

The role of several immunohistochemical markers in the determination of lung origin in metastatic disease is important. Some of these markers include TTF-1, monoclonal, and polyclonal napsin A. With regards to thyroid metastasis of lung origin, TTF-1 may not be helpful as it can be positive in the both conditions (14). The appropriate use of immunohistochemistry may help the diagnosis and may avoid unnecessary surgery for the thyroid gland (1).

If there is single thyroid metastasis, the patient should be assessed for isolated thyroidectomy. Patients present with multiple metastasis are unfitting candidate for surgery, systemic treatment such as chemotherapy or targeted therapy is more appropriate. There is no position for radioactive iodine 131I in the treatment of intrathyroid metastases (15).

In the management of patients with nonthyroid metastases, targeted therapies might be considered but its role still undetermined. There was one case report describing metastasis of a lung primary cancer with an epidermal growth factor receptor (EGFR) mutation to the thyroid gland, and erlotinib was started. The patient had an obvious clinical and radiographic improvement in the lung and thyroid mass (16). Our patient was positive for ROS1 treated with targeted therapy as a front line for her metastatic disease with a very good response.

Cases of thyroid cancer metastasizing from the lungs are rare. A high index of suspicion is required, given the vague presentation. For patients without a history of preceding malignancy, atypical presentations like in our case should always raise the suspicion of a metastatic disease because of the critical distinction in the therapeutic approach. To our knowledge, this is the first case of thyroid gland metastasis in NSCLC patient with ROS1 rearrangement to be described in the medical literature.

CONFLICT of INTEREST

The authors reported no conflict of interest related to this article.

AUTHORSHIP CONTRIBUTIONS

Concept/Design: EE, DCG

Analysis/Interpretation: EE, DCG, TKS

Data Acquisition: EE, DCG, IG

Writing: EE, DCG, TKS

Clinical Revision: All of authors

Final Approval: All of authors

REFERENCES

1. Hulikal N, Naru RR, Gangasani R, Nandyala R, Pai A, Meenakshisundaram M. A case of synchronous isolated thyroid metastasis from a primary lung cancer presenting as thyroid primary: Diagnostic challenge! *Lung India* 2016; 33: 326-9.
2. Shimaoka K, Sokal JE, Pickren JW. Metastatic neoplasms in the thyroid gland. *Pathol Clin Find Cancer* 1962; 15: 557-65.
3. McCabe DP, Farrar WB, Petkov TM, Finkelmeier W, O'Dwyer P, James A. Clinical and pathologic correlations in disease metastatic to the thyroid gland. *Am J Surg* 1985; 150(4): 519-23.
4. Battistella E, Pomba L, Mattara G, Franzato B, Toniato A. Metastases to the thyroid gland: review of incidence, clinical presentation, diagnostic problems and surgery, our experience. *J Endocrinol Investn* 2020; 43(11): 1555-60.
5. Willis RA. Metastatic tumours in the thyroid gland. *Am J Pathol* 1931; 7(3): 187-208.
6. Boston OV. The function of the vertebral veins and their role in the spread of metastasis. *Ann Surg* 1940; 112(1): 138-49.
7. Moghaddam PA, Cornejo KM, Khan A. Metastatic carcinoma to the thyroid gland: a single institution 20-year experience and review of the literature. *Endocr Pathol* 2013; 24(3): 116-24.
8. Chung AY, Tran TB, Brumund KT, Weisman RA, Bouvet M. Metastases to the thyroid: a review of the literature from the last decade. *Am Thyroid Assoc* 2012; 22(3): 258-68.

9. Lam KY, Lo CY. Metastatic tumors of the thyroid gland: A study of 79 cases in Chinese patients. *Arch Pathol Lab Med* 1998; 122(1): 37-41.
 10. Watanabe I, Tsuchiya A. Secondary carcinoma of the thyroid gland. *Jpn J Surg* 1980;10:130-6.
 11. Namad T, Wang J, Shipley R, Abdel Karim N. Thyroid metastasis from non-small cell lung cancer. *Case Rep Oncol Med* 2013; 2013: 208213.
 12. Kim TY, Kim WB, Gong G, Hong SJ, Shong YK. Metastasis to the thyroid diagnosed by fine-needle aspiration biopsy. *Clin Endocrinol* 2005; 62(2): 236-41.
 13. Yamazaki H, Iwasaki H, Yamashita T, Yoshida T, Suganuma N, Yamanaka T, et al. A case of pneumothorax after treatment with lenvatinib for anaplastic thyroid cancer with lung metastasis. *Case Rep Endocrinol* 2018; 2018: 7875929.
 14. Jagirdar J. Application of immunohistochemistry to the diagnosis of primary and metastatic carcinoma to the lung. *Arch Pathol Lab Med* 2008; 132: 384-96.
 15. Wood K, Vini L, Harmer C. Metastases to the thyroid gland: the Royal Marsden experience. *Eur J Surg Oncol* 2004; 30(6): 583-8.
- Albany C, Jain A, Ulbright TM, Einhorn LH. Lung cancer, thyroid cancer or both: an unusual case presentation. *J Thorac Dis* 2011; 3(4): 271-3.